Libyan Journal of Health, Science, and Development
(ISSN: 3106-4787)
Volume 2, Issue 3, 2026, Pages: 38 - 44
Journal homepage: https://ljhsd.org.ly/index.php/ljhsd/index
Directory of Online Libyan Journals

(ARTICLE)

Fluoroscopic X-ray Imaging in Cardiac Catheterization and Coronary Angiography: A Retrospective Study at Tobruk Medical Center, Libya

Abeer I. Suliman [1]*, Eman.Y. Abelsameh[2], Sulayman.S.Sulayman [3], Huda. M. Ibrahim[4]

[1-4] Department of Radiology, Faculty of Health Sciences, Tobruk University of Tobruk, Tobruk, Libya.

التصوير بالأشعة السينية التنظيرية في عمليات قسطرة القلب وتصوير الأوعية التاجية: دراسة استعادية في: في مركز طبرق الطبي، ليبي

عبير إبراهيم سليمان [1]*، إيمان يوسف عبد السميع [2], سليمان صالح سليمان [3]، هدى محمد إبراهيم[4]

قسم الأشعة، كلية العلوم الصحية، جامعة طبرق، طبرق، ليبيا

Publication history: **Received on** 17 Novamber 2026; **Accepted on** 25 Novamber ; **Published on** 26 Novamber

ABSTRACT:

Background: Cardiac catheterization is used for the diagnosis and treatment of a wide range of cardiovascular diseases, with procedures performed under real-time fluoroscopic X-ray guidance. Objective: To describe the distribution of diagnostic and interventional cardiac catheterization procedures recorded at Tobruk Medical Center, Libya. Methods: A retrospective descriptive review of cardiac catheterization records was conducted for procedures performed from 2018 to 2022. Data were summarized using frequencies and percentages for sex, year of procedure, and recorded diagnosis. Results: A total of 551 cardiac catheterization cases were identified. Male patients represented a higher proportion of cases than female patients, and the highest number of diagnostic cardiac catheterization procedures was recorded in 2019, with 155 cases. Conclusion: The findings provide baseline information on cardiac catheterization patterns at Tobruk Medical Center and highlight the importance of local diagnostic and interventional cardiac services.

KEYWORDS: Cardiac catheterization, Tobruk Medical Center, Coronary angiography, X-ray imaging, Pulmonary Arterial Hypertension (PAH)

ملخص :

خلفية البحث: يُستخدم قسطرة القلب في تشخيص وعلاج مجموعة واسعة من أمراض القلب والأوعية الدموية، حيث تُجرى هذه العمليات تحت توجيه الأشعة السينية (التنظير التألقي) بشكل فوري. الهدف: وصف توزيع إجراءات قسطرة القلب التشخيصية والعلاجية (التداخلية) المسجلة في مركز طبرق الطبي، ليبيا. المنهجية: أُجريت مراجعة وصفية بأثر رجعي لسجلات قسطرة القلب للحالات التي خضعت للإجراءات في الفترة ما بين عامي 2018 و2022. تم تلخيص البيانات باستخدام التكرارات والنسب المئوية وفقاً للجنس، وسنة إجراء العملية، والتشخيص المسجل. النتائج: تم رصد ما مجموعه 551 حالة خضعت لقسطرة القلب. شكل الذكور نسبة أكبر من الحالات مقارنة بالإناث، وسُجل أكبر عدد من عمليات قسطرة القلب التشخيصية في عام 2019، بواقع 155 حالة. الاستنتاج: توفر هذه النتائج معلومات أساسية حول أنماط قسطرة القلب في مركز طبرق الطبي، وتُبرز أهمية الخدمات التشخيصية والعلاجية القلبية المتاحة محلياً.

لكلمات المفتاحية: قسطرة القلب، مركز طبرق الطبي، تصوير الشرايين التاجية، التصوير بالأشعة السينية، ارتفاع ضغط الشريان الرئوي(PAH)

INTRODUCTION

Cardiac catheterization is an invasive cardiovascular procedure involving the insertion of a flexible catheter into the heart's chambers or coronary vessels. It serves both diagnostic and therapeutic purposes across a wide spectrum of cardiovascular disorders (Scanlon et al., 1999). Procedures are typically conducted in specialized cardiac catheterization laboratories equipped with fluoroscopic imaging, real-time hemodynamic and electrocardiographic (ECG) monitoring, and specialized interventional equipment such as stents, balloons, and vascular access kits. Coronary angiography remains a primary diagnostic application of cardiac catheterization, enabling two-dimensional fluoroscopic visualization of the coronary arterial lumen to detect stenosis or occlusion. The coronary arteries, situated within the epicardium, can be selectively cannulated to evaluate vessel patency. When significant luminal narrowing occurs typically defined as an occlusion exceeding 70%—**Percutaneous Coronary Intervention (PCI)** may be performed to restore coronary blood flow using balloon angioplasty or stent deployment (Khan & Ludman, 2022). Conversely, in cases of severe multi-vessel involvement (e.g., three-vessel disease), patients are frequently referred for surgical revascularization via **Coronary Artery Bypass Grafting (CABG)** in figure 1. Furthermore, cardiac catheterization provides essential invasive measurements of intracardiac pressures and blood flow dynamics, assisting in the management of high-risk patients, including those recovering from out-of-hospital cardiac arrest, heart failure, or cardiogenic shock.

Clinical Procedural Approaches

Left Heart Catheterization (LHC)

Left heart catheterization primarily focuses on evaluating left ventricular hemodynamics and coronary anatomy. Access is typically gained via arterial puncture most commonly using the **radial or femoral artery** in figure 2.

- Radial arterial access is associated with lower rates of major bleeding and vascular complications than femoral access in patients undergoing coronary angiography or intervention (Jolly SS et al., 2011).
- A catheter is advanced retrogradely into the ascending aorta and seated within the coronary ostia, allowing radiopaque contrast injection for dynamic coronary visualization.

Right Heart Catheterization (RHC)

Right heart catheterization assesses venous and pulmonary vascular hemodynamics using a pulmonary artery catheter (e.g., Swan-Ganz catheter). Access is achieved strictly through venous entry typically via the **internal jugular vein** or **femoral vein** utilizing standard introducer sheaths. in figure 2.

Once introduced, the balloon-tipped catheter is advanced through the right atrium, right ventricle, and
direct measurement or calculation of crucial hemodynamic parameters, including:

- Right Atrial Pressure (RAP)
- Right Ventricular Pressure (RVP)
- Pulmonary Artery Pressure (PAP)
- Pulmonary Capillary Wedge Pressure (PCWP)
- Systemic Vascular Resistance (SVR)
- Pulmonary Vascular Resistance (PVR)
- Mixed Venous Blood Oxygenation (SvO_2)



Figure 1. Diagnostic Cardiac Catheterization and Coronary Angiography.

Additionally, RHC allows for the determination of **Cardiac Output (CO)** and **Cardiac Index (CI)**, primarily evaluated through the **Fick principle** or **thermodilution** techniques. RHC is vital in managing pulmonary hypertension, severe heart failure, and cardiogenic shock, and can be utilized for temporary bedside monitoring in Intensive Care Units (ICUs) or for implanting continuous monitoring devices (e.g., CardioMEMS).

Procedural Risks and Comorbidities

While cardiac catheterization is generally safe, it carries inherent procedural risks:

- **Radiation Exposure:** Fluoroscopic visualization uses ionizing radiation; therefore, radiation dose should be minimized through appropriate imaging protocols, optimized geometry, and adherence to radiation-protection principles (Balter S et al., 1983).
- **Contrast-associated acute kidney injury** is a potential complication following iodinated contrast administration, particularly in patients with pre-existing renal impairment or other risk factors (American College of Radiology; 2025).
- **High-Risk Comorbidities:** Patient-related risk factors significantly increase the likelihood of adverse events during catheterization. High-risk conditions include advanced age, obesity, diabetes mellitus, uncontrolled hypertension, chronic kidney disease (CKD), extensive three-vessel coronary artery disease, unstable angina, and severe aortic stenosis.

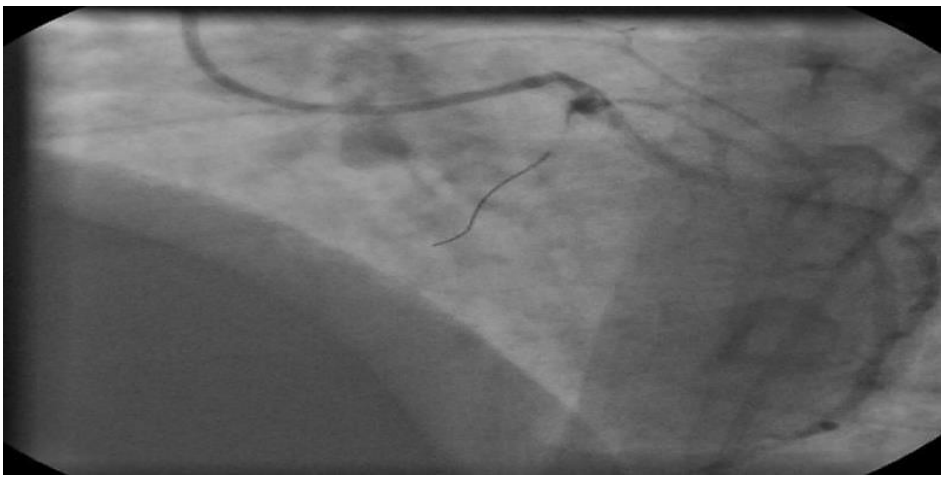

Figure 2. Coronary Angiography and Guidewire Advancement into the Coronary Artery.

[1] Context & Introductory Paragraph

The procedures included diagnostic cardiac catheterization and interventional procedures such as coronary artery stenting. The available records were used to describe the clinical diagnoses and annual distribution of procedures.

[2] Data Analysis

Data were summarized using descriptive statistics. Frequencies and percentages were calculated for categorical variables, including sex, year of procedure, and recorded diagnosis. No imputation method was specified because the present analysis was descriptive and based on available records.

[3] Results and Discussion

Right heart catheterization is the reference standard for confirming pulmonary hypertension and provides direct hemodynamic measurements that are important for diagnosis and clinical decision-making (Matusov, 2025).

Because patients with pulmonary hypertension may be hemodynamically fragile, invasive catheterization requires careful patient selection and monitoring. Contemporary studies have nevertheless reported relatively low rates of serious complications when procedures are performed in experienced centers (American College of Radiology; 2025- Hofmann LV et al., 2004 -Hoeper MM et al., 2006).

In 2007, Taylor et al. reported a 5-year single-center experience of catheterization under general anesthesia in 70 pediatric patients; four patients required external cardiac massage and one of these patients died (Taylor CJ et al., 2007).

The largest registry assessing catheterization outcomes in pulmonary hypertension to date was a 2006 multicenter study involving over 7,000 procedures conducted at high-volume medical centers in adult patients. Their findings demonstrated a very low incidence of serious adverse events (1.1%) and a low procedural mortality rate of 0.06%. Additionally, results from the Mid-Atlantic Group of Interventional Cardiology (MAGIC) registry—a 2010 multicenter collaborative of pediatric interventional cardiologists demonstrated a 4.0% complication rate across 177 pediatric catheterizations, with zero procedural deaths.

In the present study, data were collected between 2018 and 2022 at Tobruk Medical Center, Department of Cardiac Care. A total of 551 cardiac catheterization cases were identified among patients from Tobruk City and surrounding areas in figure 4.

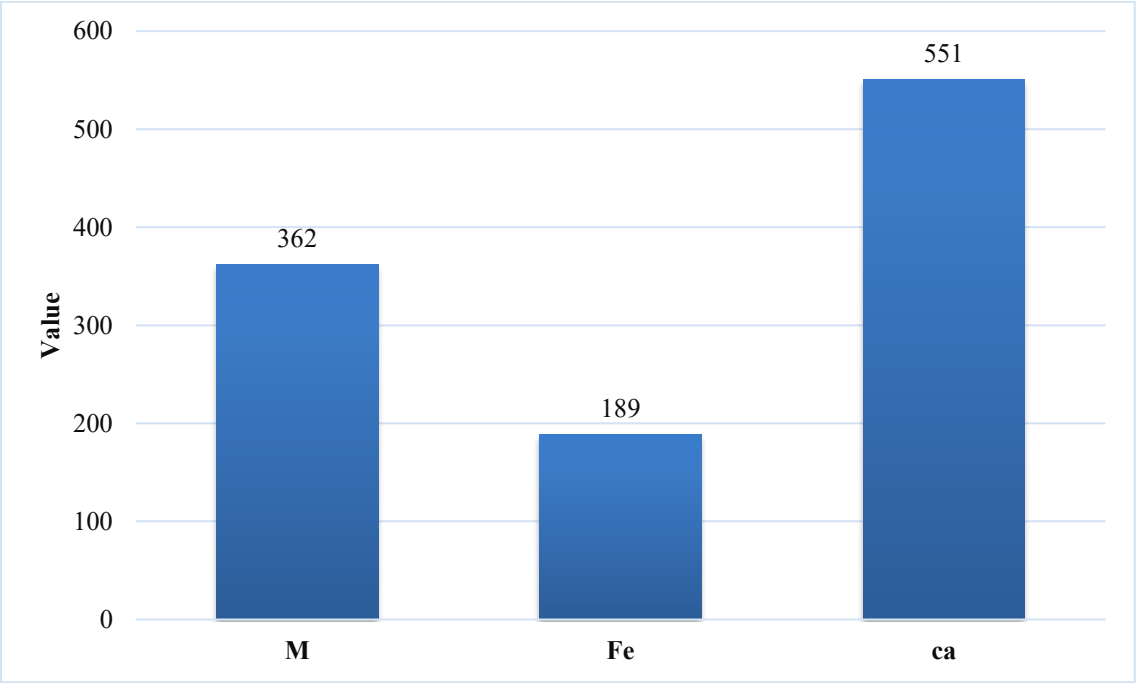

Figure 3. Distribution of Cardiac Catheterization Cases According to Sex

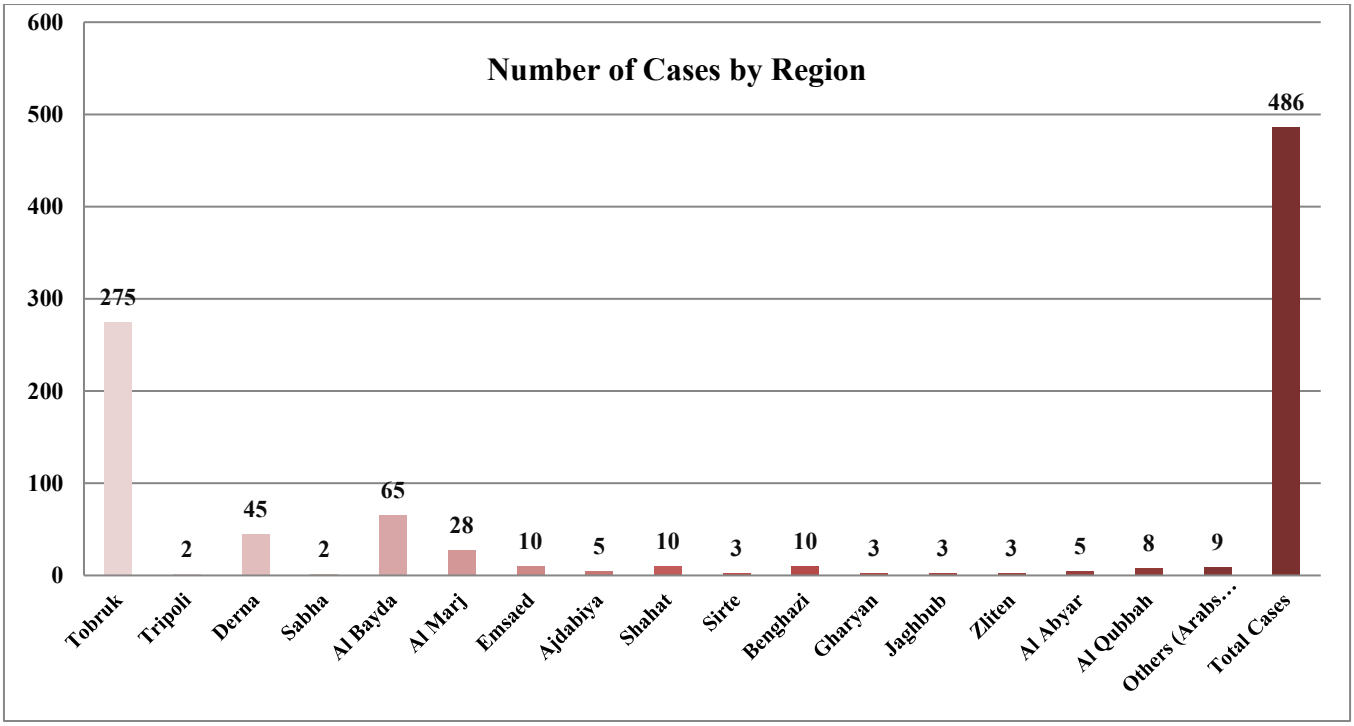

Figure 4. Distribution of Cardiac Catheterization Cases According to Diagnosis

Statistical analysis of cardiac catheterization cases during the study period showed that the number of male patients was higher than that of female patients. The highest number of diagnostic cardiac catheterization procedures was recorded in 2019, with a total of 155 cases.

During the study period, male patients represented a higher proportion of cardiac catheterization cases than female patients. A total of 551 cases were recorded among patients from Tobruk City and the surrounding areas in Figure 3.

MATERIALS AND METHODS

Study Design and Setting

A retrospective descriptive study was conducted to evaluate the patterns of fluoroscopic X-ray imaging used during cardiac catheterization and coronary angiography at Tobruk Medical Center, Libya. The study was based on cardiac catheterization records available at the Department of Cardiac Care during the study period.

Study Population

The study population consisted of patients who underwent cardiac catheterization and coronary angiography at Tobruk Medical Center during the study period. A total of 551 cases were identified from the available records. The study population included both male and female patients from Tobruk City and the surrounding areas in figure 4.

Data Collection

Data were retrospectively collected from the available cardiac catheterization records. The variables reviewed included patient sex, year of the procedure, and recorded cardiac diagnosis. The available records were also reviewed to characterize the use of fluoroscopic X-ray imaging during cardiac catheterization and coronary angiography.

Fluoroscopic X-ray Imaging

Cardiac catheterization and coronary angiography were performed under fluoroscopic X-ray guidance. Fluoroscopic imaging was used to provide real-time visualization of the catheter and contrast-enhanced coronary vessels during the procedures. The imaging system enabled visualization of the coronary anatomy and supported catheter positioning and image-guided assessment of the coronary arteries (Hill KD et al., 2010).

Data Analysis

The collected data were organized and analyzed using descriptive statistical methods. Frequencies and percentages were calculated for categorical variables, including sex and diagnostic categories. The annual distribution of cardiac catheterization cases was also assessed. The results were presented using tables and graphical representations to demonstrate the distribution of cases during the study period.

Ethical Considerations

The study was conducted using retrospective clinical records, with patient information treated confidentially. No personally identifiable patient information was included in the analysis or presentation of the results. Ethical approval and/or institutional permission should be stated according to the actual approval obtained from the relevant authority at Tobruk Medical Center.

CONCLUSION

This study provides valuable baseline data on cardiac catheterization patterns at Tobruk Medical Center from 2018 to 2022. The findings highlight a predominant distribution among male patients and demonstrate that local diagnostic and interventional services serve a crucial role in managing cardiovascular diseases in eastern Libya. Expanding facilities and adopting modern low-dose radiation protocols are recommended to further improve patient care.

ACKNOWLEDGMENTS

The authors would like to express their sincere gratitude to the medical, nursing, and administrative staff at the Department of Cardiac Care, Tobruk Medical Center, for their support and assistance in facilitating data collection for this study.

ETHICS

Ethics statement: Ethical approval and/or institutional permission must be reported using the actual approval information obtained from the relevant authority at Tobruk Medical Center. The current manuscript should not be submitted with this placeholder statement.

REFERENCES

American College of Radiology. ACR Manual on Contrast Media. Reston, VA: American College of Radiology; 2025.
Balter S, Borrás C, Lin PJP, et al. Evaluation of radiation exposure levels in cine cardiac catheterization laboratories. AAPM Report No. 12. New York, NY: American Institute of Physics; 1983.

Hill KD, Lim DS, Everett AD, Ivy DD, Moore JD. Assessment of pulmonary hypertension in the pediatric catheterization laboratory: current insights from the MAGIC registry. Catheter Cardiovasc Interv. 2010;76(6):865-873. doi:10.1002/ccd.22693.

Hoeper MM, Lee SH, Voswinckel R, et al. Complications of right heart catheterization procedures in patients with pulmonary hypertension in experienced centers. J Am Coll Cardiol. 2006;48(12):2546-2552. doi: 10.1016/j.jacc.2006.07.061.

Hofmann LV, Lee DS, Gupta A, et al. Safety and hemodynamic effects of pulmonary angiography in patients with pulmonary hypertension: 10-year single-center experience. AJR Am J Roentgenol. 2004;183(3):779-786. doi:10.2214/ajr.183.3.1830779.

Jolly SS, Yusuf S, Cairns J, et al. Radial versus femoral access for coronary angiography and intervention in patients with acute coronary syndromes (RIVAL): a randomised, parallel group, multicentre trial. Lancet. 2011;377(9775):1409-1420. doi:10.1016/S0140-6736(11)60404-2.

Khan SQ, Ludman PF. Percutaneous coronary intervention. Medicine. 2022;50(7):437-444. doi:10.1016/j.mpmed.2022.04.008.

Matusov Y, Kolaitis NA, Geft D, et al. Best practices for right heart catheterization in the diagnosis of pulmonary hypertension. Chest. 2025;168(3):763-779. doi: 10.1016/j.chest.2025.05.009.

Scanlon PJ, Faxon DP, Audet AM, et al. ACC/AHA guidelines for coronary angiography: a report of the American College of Cardiology/American Heart Association Task Force on Practice Guidelines (Committee on Coronary Angiography). J Am Coll Cardiol. 1999;33(6):1756-1824. doi:10.1016/S0735-1097(99)00126-6.

Taylor CJ, Derrick G, McEwan A, Haworth SG, Sury MRJ. Risk of cardiac catheterization under anaesthesia in children with pulmonary hypertension. Br J Anaesth. 2007;98(5):657-661. doi:10.1093/bja/aem059.